



Inspection Report

Carson & Barnes Circus
P. O. Box J
Hugo, OK 74743

Customer ID: **3954**

Certificate: **73-C-0001**

Site: 001

CARSON & BARNES CIRCUS

Type: ROUTINE INSPECTION

Date: Jan-05-2015

2.40 (b) (3)

ATTENDING VETERINARIAN AND ADEQUATE VETERINARY CARE (DEALERS AND EXHIBITORS).

The facility is not utilizing a mechanism to identify, convey, or document treatment of veterinary problems with some of the animals.

**A female Asian elephant, Nina, has been losing weight and in thin body condition since early 2013. Body weights were taken on 12/19/2013 (5780 lbs), 4/3/2014 (5774 lbs), 11/19/2014 (5386 lbs), and on 12/8/2014 (5280 lbs). The consulting veterinarian has provided guidance regarding increasing the diet and nutritive value of the diet for this elephant but there is not any guidance regarding what percentage of body weight loss would be of concern and would require additional veterinary oversight. This animal has lost 500 lbs in the past 7-8 months, a significant weight loss of 8.7% of total body weight.

**Two female Asian elephants, Rosie and Opal, are being treated for stiffness/arthritis with acupuncture and hydrotherapy but this was not prescribed by the attending or consulting veterinarians nor is there documentation as part of the program of veterinary care to show the veterinarians for the facility have approved this treatment plan, treatment goals, nor when there should be a re-evaluation of or change in treatment. The person conducting this treatment was trained by a person who is not a veterinarian nor is accredited to perform acupuncture for veterinary purposes.

**A female pygmy hippo, Katie, was noted to be losing weight and not doing well while traveling for exhibition purposes in May 2014. The consulting veterinarian was contacted and the animal was brought to the home facility on 5/16/2014. The consulting veterinarian evaluated the animal on 5/22/2014 and prescribed medication for possible dental disease but there are no records to show that the treatment was given. The hippo was observed 3 more times briefly by the consulting veterinarian (August, September, and October) but the animal was found dead on 11/14/2014. It was determined on the necropsy by the consulting veterinarian that the animal's "body condition is poor with prominent dorsal vertebral spines, illial wings of the hips are visible" and that the most likely cause of death was a heart condition (dilated cardiomyopathy). No weights were ever obtained on the animal and no documentation for daily observation was made to note if her body condition was deteriorating prior to her death.

Documentation of veterinary conditions, prescribed treatments, and chronic problems that are being monitored is an important component of a functional program for adequate veterinary care as it provides a mechanism for communication between animal care staff and the veterinarians and to ensure that care is

Prepared By:

TRACY A THOMPSON, D.V.M. USDA, APHIS, Animal Care

Date:

Title:

VETERINARY MEDICAL OFFICER Inspector 5044

Jan-06-2015

Received By:

KRISTIN PARRA

Date:

Title:

LICENSEE

Jan-06-2015



Inspection Report

provided as directed and that the expected outcome is achieved.

******A male llama, Bandit, was noted to have excessively overgrown hooves such that the toes, especially right front and left hind, were curving to the sides. The llama was under veterinary care for an eye problem but no one had noticed or addressed the overgrown hooves.

Excessive growth of hooves changes the angle of the toes, changes the gait, and can lead to chronic problems in the feet and legs such as arthritis.

Daily observation of all animals to assess their health and well-being may be accomplished by someone other than the attending veterinarian and that a mechanism of direct and frequent communication is required so that timely and accurate information on problems of animal health, behavior, and well-being is conveyed to the attending veterinarian.

The llama "Bandit" shall have his hooves trimmed by 1/10/2015.

A mechanism for communication of veterinary conditions, treatment, and daily observation shall be established and maintained by 1/17/2015.

Inspection conducted with facility representatives and APHIS AC VMO's on 1/5-6/2014. Exit briefing conducted with facility representatives on 1/6/2014.

Asian elephants inspected: Tommy, Oberto, Hugo, Rosie, Opal, Margaret, Nina, Viola, Kelly, Libby, Alta, Lisa, Beckie, Tracy, Bunny, Suzy, Isa, Lily, Val, Zola, Lulu, Chang, Whimpy, DelRita, Isla.

Prepared By:

TRACY A THOMPSON, D.V.M. USDA, APHIS, Animal Care

Title: VETERINARY MEDICAL OFFICER Inspector 5044

Date:

Jan-06-2015

Received By:

KRISTIN PARRA

Title: LICENSEE

Date:

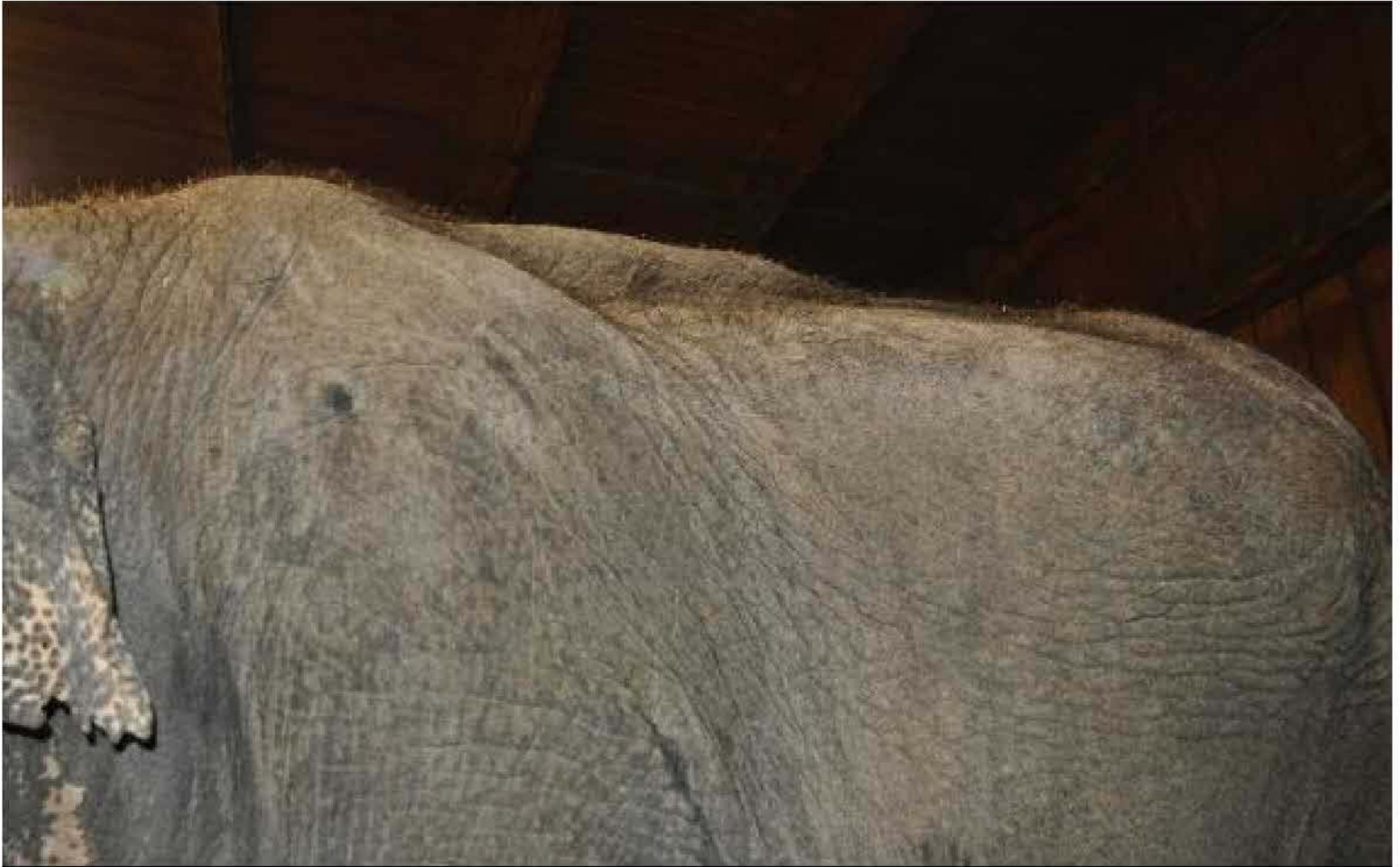Jan-06-2015



Animals Inspected at Last Inspection

| Cust No | Cert No | Site | Site Name | Inspection |
|---------|-----------|------|------------------------|------------|
| 3954 | 73-C-0001 | 001 | CARSON & BARNES CIRCUS | Jan-05-15 |

| Count | Species |
|--------|------------------|
| 000001 | LLAMA |
| 000001 | ZEBU |
| 000019 | GOAT |
| 000025 | ASIATIC ELEPHANT |



CFR: 2.40 (b) (3)

| | | | |
|---------------|--|------------------------|-----------|
| Photographer: | Debbie Cunningham | Legal Name: | 73-C-0001 |
| Photo Taken: | Mon, Jan 5, '15 | CARSON & BARNES CIRCUS | |
| Inspection: | 6151302270141 | | |
| Description: | Asian elephant, Nina, in emaciated condition. Has lost 500 lbs since April 2014. | | |




CFR: 2.40 (b) (3)

| | | | |
|---------------|--|------------------------|-----------|
| Photographer: | Debbie Cunningham | Legal Name: | 73-C-0001 |
| Photo Taken: | Mon, Jan 5, '15 | CARSON & BARNES CIRCUS | |
| Inspection: | 6151302270141 | | |
| Description: | Asian elephant, Nina, in emaciated condition. Has lost 500 lbs since April 2014. | | |



CFR: 2.40 (b) (3)

| | | | |
|---------------|--|------------------------|-----------|
| Photographer: | Debbie Cunningham | Legal Name: | 73-C-0001 |
| Photo Taken: | Mon, Jan 5, '15 | CARSON & BARNES CIRCUS | |
| Inspection: | 6151302270141 | | |
| Description: | Asian elephant, Nina, in emaciated condition. Has lost 500 lbs since April 2014. | | |



CFR: 2.40 (b) (3)

| | | | |
|---------------|--|------------------------|-----------|
| Photographer: | Debbie Cunningham | Legal Name: | 73-C-0001 |
| Photo Taken: | Mon, Jan 5, '15 | CARSON & BARNES CIRCUS | |
| Inspection: | 6151302270141 | | |
| Description: | Asian elephant, Nina, in emaciated condition. Has lost 500 lbs since April 2014. | | |

11/19/14

| | |
|--------|------|
| Nina | 5280 |
| Lilly | 7935 |
| Tracy | 6830 |
| Sue | 7068 |
| Opal | 6475 |
| Rosie | 7338 |
| Alta | 729 |
| Delita | 847 |
| Wimpy | 77 |
| Hope | |

CFR: 2.40 (b) (3)

Photographer: Debbie Cunningham

Legal Name:

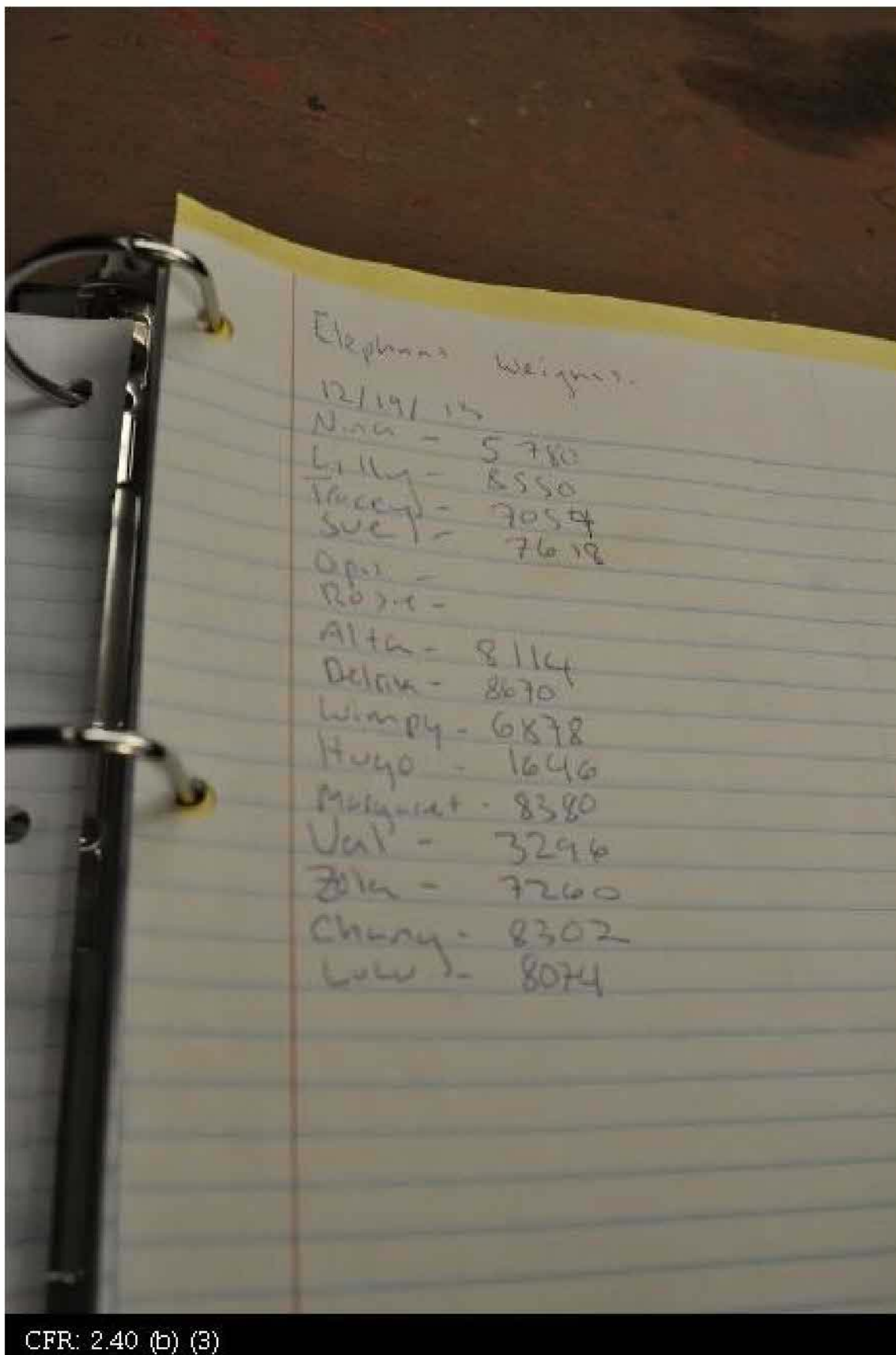
73-C-0001

CARSON & BARNES CIRCUS

Photo Taken: Mon, Jan 5, '15

Inspection: 6151302270141

Description: Weight records provided during inspection; Nina has lost 500 pounds (~8.7% total body weight) in less than 1 year



CFR: 2.40 (b) (3)

Photographer: Debbie Cunningham

Legal Name:

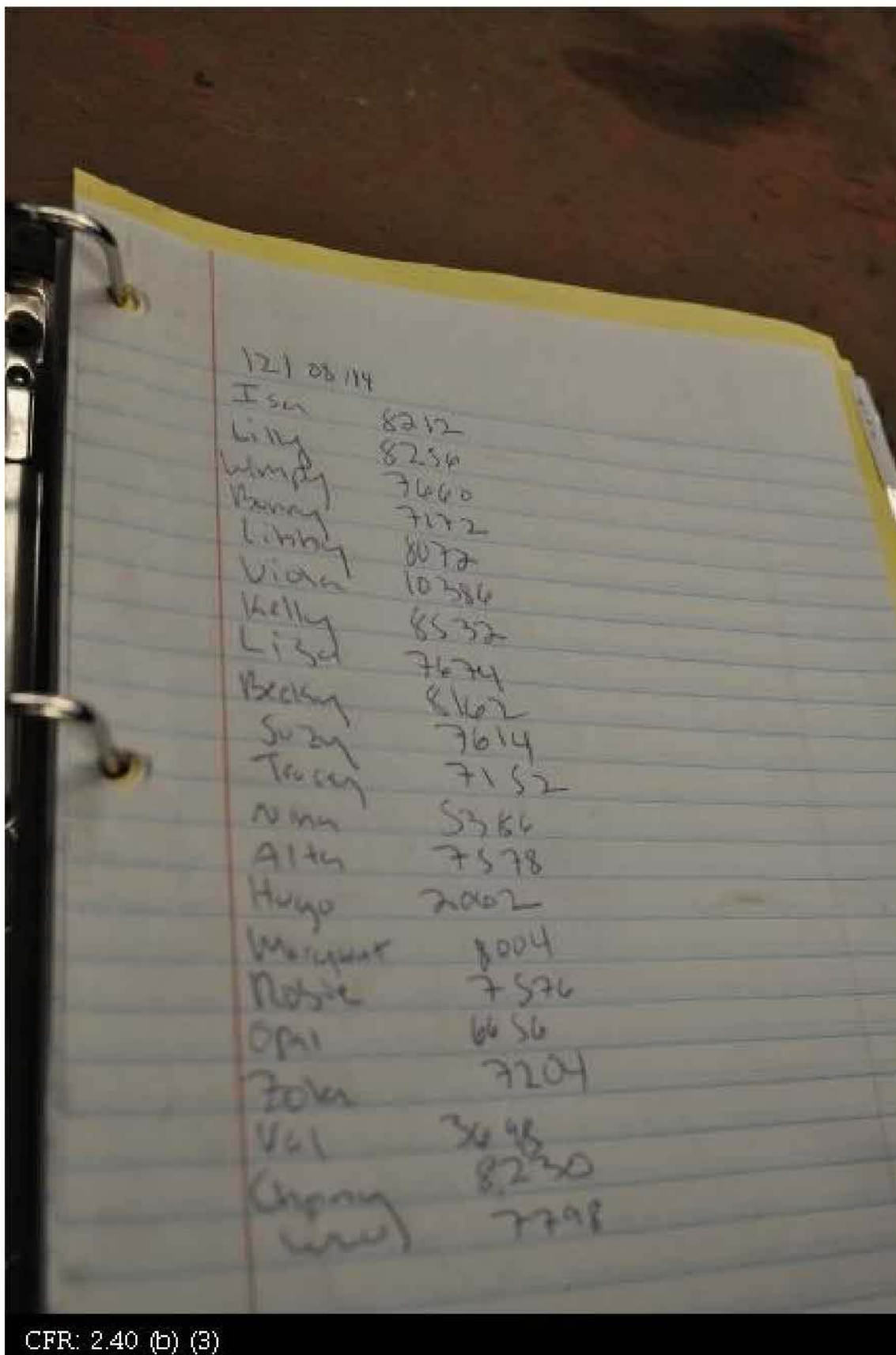
73-C-0001

CARSON & BARNES CIRCUS

Photo Taken: Mon, Jan 5, '15

Inspection: 6151302270141

Description: Weight records provided during inspection; Nina has lost 500 pounds (~8.7% total body weight) in less than 1 year



CFR: 2.40 (b) (3)

Photographer: Debbie Cunningham

Legal Name:

73-C-0001

CARSON & BARNES CIRCUS

Photo Taken: Mon, Jan 5, '15

Inspection: 6151302270141

Description: Weight records provided during inspection; Nina has lost 500 pounds (~8.7% total body weight) in less than 1 year



CFR: 2.40 (b) (3)

| | | | |
|---------------|---|------------------------|-----------|
| Photographer: | Debbie Cunningham | Legal Name: | 73-C-0001 |
| Photo Taken: | Mon, Jan 5, '15 | CARSON & BARNES CIRCUS | |
| Inspection: | 6151302270141 | | |
| Description: | Close up photos of feet for male llama, Bandit; excessively overgrown hooves with curling of the toes | | |



CFR: 2.40 (b) (3)

| | | | |
|---------------|---|------------------------|-----------|
| Photographer: | Debbie Cunningham | Legal Name: | 73-C-0001 |
| Photo Taken: | Mon, Jan 5, '15 | CARSON & BARNES CIRCUS | |
| Inspection: | 6151302270141 | | |
| Description: | Close up photos of feet for male llama, Bandit; excessively overgrown hooves with curling of the toes | | |



CFR: 2.40 (b) (3)

| | | | |
|---------------|---|------------------------|-----------|
| Photographer: | Debbie Cunningham | Legal Name: | 73-C-0001 |
| Photo Taken: | Mon, Jan 5, '15 | CARSON & BARNES CIRCUS | |
| Inspection: | 6151302270141 | | |
| Description: | Close up photos of feet for male llama, Bandit; excessively overgrown hooves with curling of the toes | | |



CFR: 2.40 (b) (3)

| | | | |
|---------------|---|------------------------|-----------|
| Photographer: | Debbie Cunningham | Legal Name: | 73-C-0001 |
| Photo Taken: | Mon, Jan 5, '15 | CARSON & BARNES CIRCUS | |
| Inspection: | 6151302270141 | | |
| Description: | Close up photos of feet for male llama, Bandit; excessively overgrown hooves with curling of the toes | | |

Carson & Barnes Circus
 2614 E. 2070 Rd.
 Hugo, OK 74743

| | | | |
|---|---|---------------------------------------|------------------------|
| | | DELIVERY BY COMMERCIAL CARRIER | |
| A DELIVERY BY ("X") ONE | | 10. TRUCK LICENSE NO. | 11. BILL OF LADING NO. |
| <input checked="" type="checkbox"/> Buyer's Truck | <input type="checkbox"/> Owner's Truck (Seller or Donor) | | |
| 12. NAME AND ADDRESS OF COMPANY OR FIRM | | 12. NAME AND ADDRESS OF TRUCK DRIVER | |

- better food 12/6-14
 - Niche home
 - water home
 12/6-14
 12/14-15
 12/15-16
 12/16-17
 12/17-18
 12/18-19
 12/19-20
 12/20-21
 12/21-22
 12/22-23
 12/23-24
 12/24-25
 12/25-26
 12/26-27
 12/27-28
 12/28-29
 12/29-30
 12/30-31
 1/1-2
 1/2-3
 1/3-4
 1/4-5
 1/5-6
 1/6-7
 1/7-8
 1/8-9
 1/9-10
 1/10-11
 1/11-12
 1/12-13
 1/13-14
 1/14-15
 1/15-16
 1/16-17
 1/17-18
 1/18-19
 1/19-20
 1/20-21
 1/21-22
 1/22-23
 1/23-24
 1/24-25
 1/25-26
 1/26-27
 1/27-28
 1/28-29
 1/29-30
 1/30-31
 2/1-2
 2/2-3
 2/3-4
 2/4-5
 2/5-6
 2/6-7
 2/7-8
 2/8-9
 2/9-10
 2/10-11
 2/11-12
 2/12-13
 2/13-14
 2/14-15
 2/15-16
 2/16-17
 2/17-18
 2/18-19
 2/19-20
 2/20-21
 2/21-22
 2/22-23
 2/23-24
 2/24-25
 2/25-26
 2/26-27
 2/27-28
 2/28-29
 2/29-30
 3/1-2
 3/2-3
 3/3-4
 3/4-5
 3/5-6
 3/6-7
 3/7-8
 3/8-9
 3/9-10
 3/10-11
 3/11-12
 3/12-13
 3/13-14
 3/14-15
 3/15-16
 3/16-17
 3/17-18
 3/18-19
 3/19-20
 3/20-21
 3/21-22
 3/22-23
 3/23-24
 3/24-25
 3/25-26
 3/26-27
 3/27-28
 3/28-29
 3/29-30
 3/30-31
 4/1-2
 4/2-3
 4/3-4
 4/4-5
 4/5-6
 4/6-7
 4/7-8
 4/8-9
 4/9-10
 4/10-11
 4/11-12
 4/12-13
 4/13-14
 4/14-15
 4/15-16
 4/16-17
 4/17-18
 4/18-19
 4/19-20
 4/20-21
 4/21-22
 4/22-23
 4/23-24
 4/24-25
 4/25-26
 4/26-27
 4/27-28
 4/28-29
 4/29-30
 4/30-5/1
 5/1-2
 5/2-3
 5/3-4
 5/4-5
 5/5-6
 5/6-7
 5/7-8
 5/8-9
 5/9-10
 5/10-11
 5/11-12
 5/12-13
 5/13-14
 5/14-15
 5/15-16
 5/16-17
 5/17-18
 5/18-19
 5/19-20
 5/20-21
 5/21-22
 5/22-23
 5/23-24
 5/24-25
 5/25-26
 5/26-27
 5/27-28
 5/28-29
 5/29-30
 5/30-5/31
 6/1-2
 6/2-3
 6/3-4
 6/4-5
 6/5-6
 6/6-7
 6/7-8
 6/8-9
 6/9-10
 6/10-11
 6/11-12
 6/12-13
 6/13-14
 6/14-15
 6/15-16
 6/16-17
 6/17-18
 6/18-19
 6/19-20
 6/20-21
 6/21-22
 6/22-23
 6/23-24
 6/24-25
 6/25-26
 6/26-27
 6/27-28
 6/28-29
 6/29-30
 6/30-7/1
 7/1-2
 7/2-3
 7/3-4
 7/4-5
 7/5-6
 7/6-7
 7/7-8
 7/8-9
 7/9-10
 7/10-11
 7/11-12
 7/12-13
 7/13-14
 7/14-15
 7/15-16
 7/16-17
 7/17-18
 7/18-19
 7/19-20
 7/20-21
 7/21-22
 7/22-23
 7/23-24
 7/24-25
 7/25-26
 7/26-27
 7/27-28
 7/28-29
 7/29-30
 7/30-7/31
 8/1-2
 8/2-3
 8/3-4
 8/4-5
 8/5-6
 8/6-7
 8/7-8
 8/8-9
 8/9-10
 8/10-11
 8/11-12
 8/12-13
 8/13-14
 8/14-15
 8/15-16
 8/16-17
 8/17-18
 8/18-19
 8/19-20
 8/20-21
 8/21-22
 8/22-23
 8/23-24
 8/24-25
 8/25-26
 8/26-27
 8/27-28
 8/28-29
 8/29-30
 8/30-8/31
 9/1-2
 9/2-3
 9/3-4
 9/4-5
 9/5-6
 9/6-7
 9/7-8
 9/8-9
 9/9-10
 9/10-11
 9/11-12
 9/12-13
 9/13-14
 9/14-15
 9/15-16
 9/16-17
 9/17-18
 9/18-19
 9/19-20
 9/20-21
 9/21-22
 9/22-23
 9/23-24
 9/24-25
 9/25-26
 9/26-27
 9/27-28
 9/28-29
 9/29-30
 9/30-10/1
 10/1-2
 10/2-3
 10/3-4
 10/4-5
 10/5-6
 10/6-7
 10/7-8
 10/8-9
 10/9-10
 10/10-11
 10/11-12
 10/12-13
 10/13-14
 10/14-15
 10/15-16
 10/16-17
 10/17-18
 10/18-19
 10/19-20
 10/20-21
 10/21-22
 10/22-23
 10/23-24
 10/24-25
 10/25-26
 10/26-27
 10/27-28
 10/28-29
 10/29-30
 10/30-10/31
 11/1-2
 11/2-3
 11/3-4
 11/4-5
 11/5-6
 11/6-7
 11/7-8
 11/8-9
 11/9-10
 11/10-11
 11/11-12
 11/12-13
 11/13-14
 11/14-15
 11/15-16
 11/16-17
 11/17-18
 11/18-19
 11/19-20
 11/20-21
 11/21-22
 11/22-23
 11/23-24
 11/24-25
 11/25-26
 11/26-27
 11/27-28
 11/28-29
 11/29-30
 11/30-1



Katie: Pygmy Hippo Necropsy 14 November 2014

Animal arrived wrapped in plastic tarp, cadaver was whole, fresh.

Integument and External condition: Overall external condition, showed no external injuries but body condition is poor with prominent dorsal vertebral spines, ilial wings of hips are visible, but ribs, and scapulae are not. Erosion to lower left mandible seen previously last spring appears healed.

GIT: Cheek teeth on all arcades are severely worn to the gum line, lower right mandibular molar fractured and impacted with feed. Esophagus normal, stomachs are full, papillae are sloughing but appear normal, minimal petechiae in final acid stomach region, and small area of actual mild gastric ulceration in one region near pylorus. Small intestines, and large intestine have normal ingesta or formed stool present. Mesentery has no fat present, and serous atrophy is present. Mild peritoneal effusion present. Liver is sharp edged and slightly friable due to post mortem change, a gall bladder is present and patent though text books state that pygmy hippos don't have a gall bladder. Pancreas watery but otherwise unremarkable.

Urogenital: Kidneys appear normal in size and shape and color, there is complete lack of retroperitoneal fat around the kidneys. Adrenals present and normal. Cut sections of kidneys show one 1.5 cm cyst present in right kidney's cortex. Ovaries have numerous cysts present, uterus is present, normal no effusion or abnormality seen.

Cardiopulmonary: Trachea is clean and dry, bronchial lymph nodes are surrounded in serous atrophied fat and are dark black in color, but of normal size and consistency. Left lung is well aerated soft on palpation and bronchioles are dry. Cut surface of lung shows black starry pattern in parenchyma. Right lung is reddened and heavy with hemostatic congestion, Parenchyma is of normal consistency and cut surface is otherwise normal. Both lungs are cut in bread like slices along their entire lengths. Heart appears enlarged and pericardial sac contains moderate amount of light straw colored fluid, heart is flabby in overall appearance with enlarged atria and thin walled saggy right ventricle, and left ventricle though not as obviously dilated also appears distended. Serous atrophy of fat on epicardial surface is present.

Hemolymphatic: spleen is small, normal in size and shape, lymph nodes overall in body are not enlarged.

Musculoskeletal: Joints that were opened appear normal, muscle condition is overall poor. Pads of feet, and toe nails appear normal, no ulcerations or other abrasions noted.

CNS: Not examined

| | | | |
|---|--|--------------------------------------|--|
| DELIVERY BY COMMERCIAL CARRIER | | BY BILL OF LADING OR | |
| 12. FORM NO. 1000-001 | | 13. NAME AND ADDRESS OF TRUCK DRIVER | |
| 14. NAME AND ADDRESS OF BUYER OR RECEIVER | | 15. NAME AND ADDRESS OF TRUCK DRIVER | |
| DELIVERY RECEIPT - TO BE COMPLETED BY BUYER OR RECEIVER | | | |
| 16. NUMBER DEAD | | 17. NUMBER ALIVE | |
| 18. DATE | | 19. DATE | |

2

Assess: Overall poor body condition and body wide serous atrophy of fat are indicative of a long term chronic disease. She had ample masticated food throughout her GIT tract and was eating well so her poor body condition is further supported from being due to chronic disease. The most significant lesion: an enlarged dilated heart looks like primary cause of chronic disease and dilated cardiomyopathy is likely cause of death. There is no sign of infectious or neoplastic disease. Her dentition changes are the result of extreme age and not uncommon in what we see here at our facility with very geriatric hooftstock. No further testing was done at this time and deemed unnecessary, but tissues are saved in formalin and freezer.

Tissues saved in formalin: heart, lung, bronchial and mesenteric lymph node, liver, kidney, stomach, ovary, uterus, brainstem, spleen.

Tissues saved in freezer: lung, bronchial lymph node, heart, liver, kidney, spleen.

Please feel free to contact me if you have further questions.

Sincerely



Kay A. Beckman, DVM, DACVP

Director of Animal Health

Tollie Zoo

(918) 469-6243

kay@tolliezoos.org

