

PEOPLE FOR
THE ETHICAL
TREATMENT
OF ANIMALS
FOUNDATION

Washington, D.C.
1536 16th St. N.W.
Washington, DC 20036
202-483-PETA

Los Angeles
2154 W. Sunset Blvd.
Los Angeles, CA 90026
323-644-PETA

Norfolk
501 Front St.
Norfolk, VA 23510
757-622-PETA

Oakland
554 Grand Ave.
Oakland, CA 94610
510-763-PETA

PETA FOUNDATION IS AN
OPERATING NAME OF FOUNDATION
TO SUPPORT ANIMAL PROTECTION.

AFFILIATES:

- PETA U.S.
- PETA Asia
- PETA India
- PETA France
- PETA Australia
- PETA Germany
- PETA Netherlands
- PETA Foundation (U.K.)

September 16, 2016

Elizabeth Goldentyer, D.V.M.
Director, Animal Welfare Operations
USDA/APHIS/AC Eastern Region

Via e-mail: aceast@aphis.usda.gov

Re: Urgent Request for Investigation of Reports of Lion and Pig in Poor Condition at
Tri-State Zoo (License No. 51-C-0064)

Dear Dr. Goldentyer:

I am writing on behalf of PETA to request that the USDA urgently investigate Tri-State Zoological Park of Western Maryland ("Tri-State"; license no. 51-C-0064) regarding reports of a lion and pig in need of veterinary attention, in apparent violation of the Animal Welfare Act (AWA).

PETA received reports from a concerned citizen who observed and documented a lion in emaciated body condition on September 11. *See Photo 1.* According to wildlife veterinarian Dr. Christine Capaldo, this animal's body condition is a 1.5 out of 5 on the Animal Welfare Inspection Guide's Body Condition Assessment Chart for lions (attached) and should be evaluated by a veterinarian immediately.


The eyewitness also documented a pig with apparent skin issues around the periorbital region of his face and behind his ears. *See Photo 2.* Dr. Capaldo stated that "the red skin behind the ears is most likely sunburn since this is an area with little hair. However, dry skin or bacterial infections can also cause red, flaky skin. Causes of conjunctival inflammation and excess tearing in pigs could be due to irritants, bacterial or viral infections, or other causes such as entropion which can cause corneal ulceration." *See Photo 3.*

Please inspect these and all animals at Tri-State, as well as their veterinary records, and ensure that they are receiving adequate veterinary care pursuant to 9 C.F.R. § 2.40. Please also inspect the nutritive value of the food that this lion is provided, in accordance with 9 C.F.R. § 3.129(a).

The eyewitness also reported observing isolated primates, dilapidated enclosures, and filthy tiger pools, which are all recurring concerns at Tri-State. Please ensure that all animals at Tri-State are provided with clean water, food, shelter, and care consistent with the mandates of the AWA and hold the facility fully accountable for any and all violations that you discover during your investigation.

Thank you for your attention to this important matter. Please inform me of the complaint number that your agency assigns to this correspondence.

Very truly yours,



Deborah Metzler, M.S.
Wildlife Specialist, Captive Animal Law Enforcement

Attachment

Photo Appendix



Photo 1: Male lion at Tri-State in emaciated body condition.

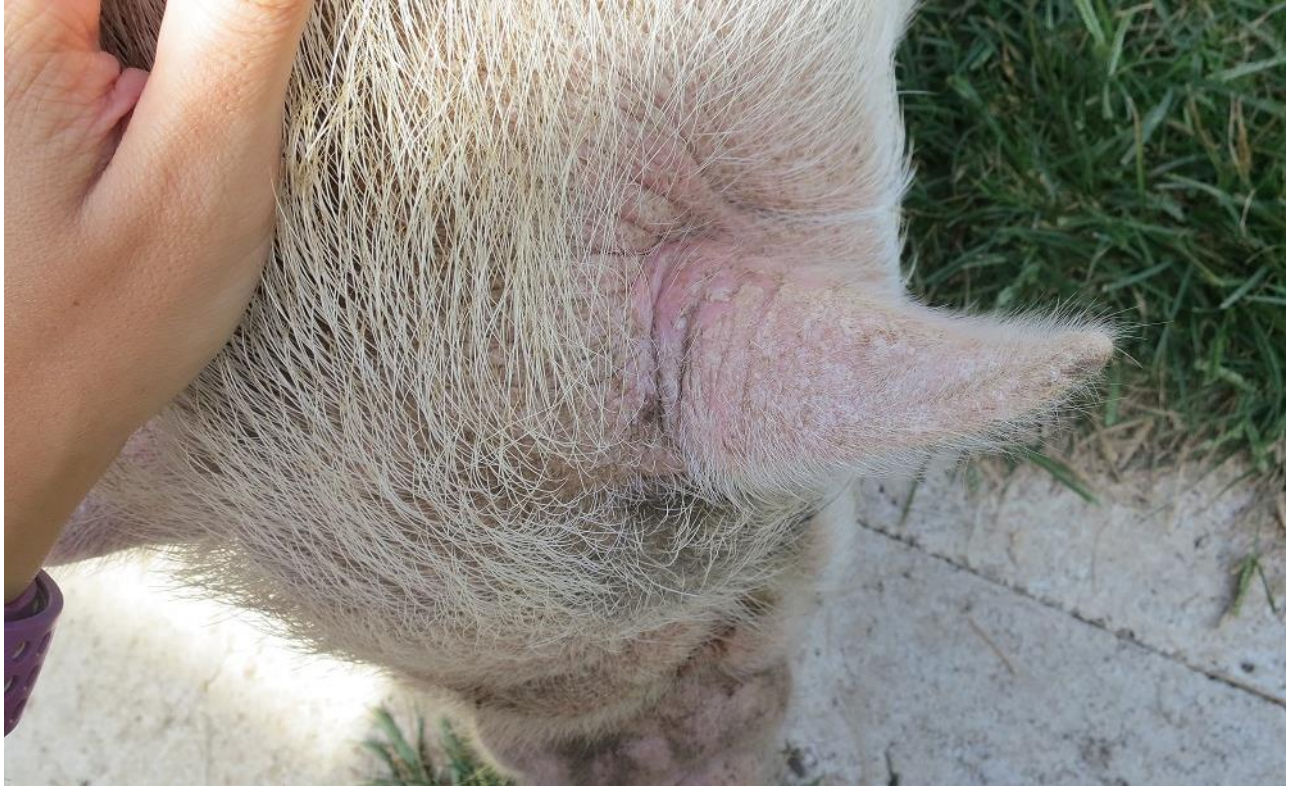

Photo 2: Pig with redness around the periorbital region and behind the ears, indicative of sunburn or other skin pathology.




Photo 3: Pig with excess tearing, which can be a sign of environmental irritants, infection, or entropion.