



VETERINARY DENTISTS without BORDERS

Veterinary Dental Report

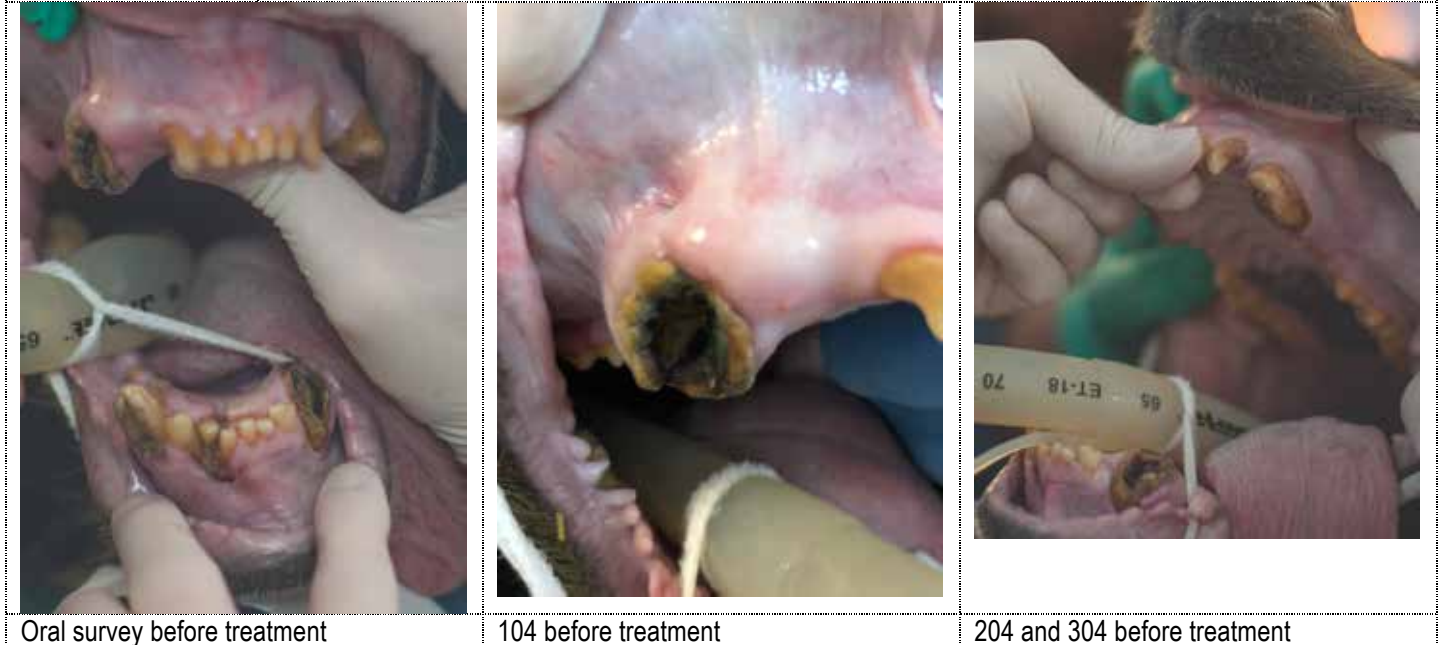
MISSION LOCATION
MISSION CODE
MISSION DATES

Wild Animal Sanctuary
 WAS08FEB20
 February 8, 2020

DATE	02/08/2020	PATIENT NAME:	Dillan	SPECIES:	Asiatic Bear
DOB/AGE:	35 yo est	SEX:	MN	ORIGIN:	PA
PATIENT "OCCUPATION":					
WEIGHT:	600 # est	ANESTHESIA:			
SURGEONS: B Hall, C Dyer, C Sitzman, P Emily					
CLINICIAN:			CARETAKERS:		
BEGIN TIME:	9:40a intubated	END TIME:	12:10p	TOTAL TIME:	2.5 hrs

NOTES:
 104: CCF open apex, draining fistula. SXX (surgical extraction). Flushed with chlorhexidine. Flap sutured w/ 2/0 Monocryl
 105, 106, 301, 302, 303, 304, 306, 401, 402, 403 – SXX. Flap sutured 2/0 Monocryl
 204: CCF (complicated crown fracture). Closed apex, quiet, no sign of periapical abscess. Treatment postponed due to time.
 304: CCF open apex. SXX. Friable tooth. Punctured apex to drain abscess. Flap closed with 2/0 Monocryl. RTR/RRT
 404: CCF open apex. Cleaned and filed to 130## file 60mm working length. Flushed with chlorhexidine/saline 50:50 mix. Apex packed with MTA to midroot, backfilled with GuttaFlow 2. Placed (3) 100## 60mm gutta percha points. Crown prep with acid etch, composite restoration, light cure.

PHOTOGRAPHS:



Oral survey before treatment 104 before treatment 204 and 304 before treatment

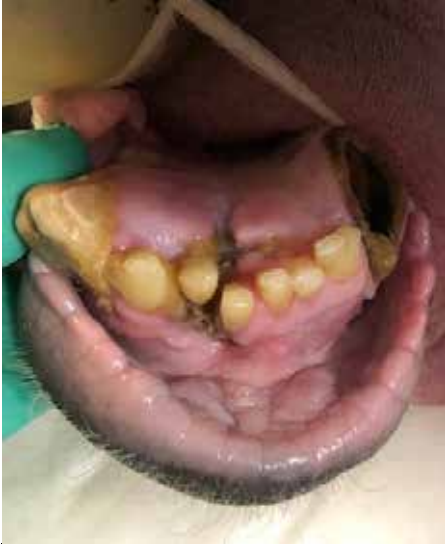

VETERINARY DENTISTS without BORDERS

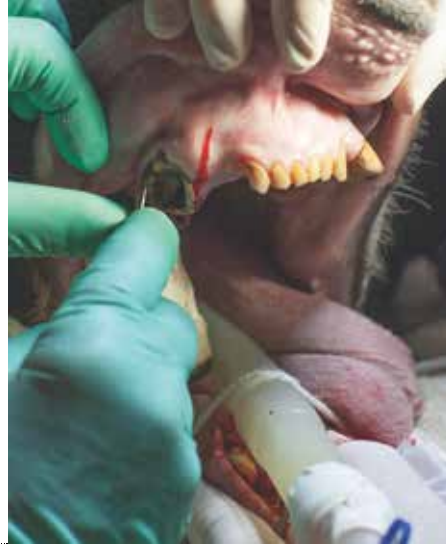Veterinary Dental Report

MISSION LOCATION
MISSION CODE
MISSION DATES

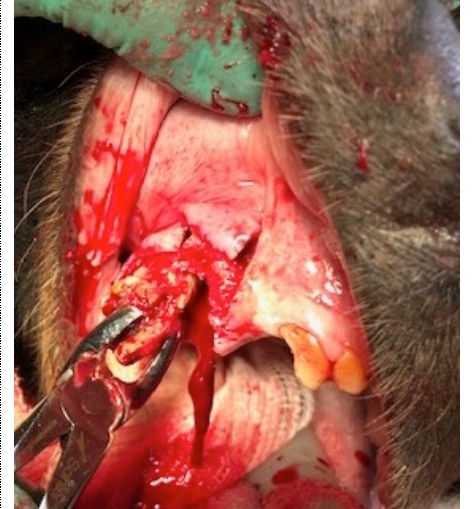Wild Animal Sanctuary
WAS08FEB20
February 8, 2020



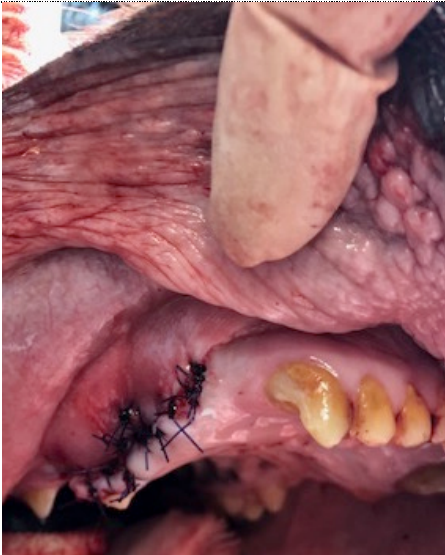304 to 404 before treatment



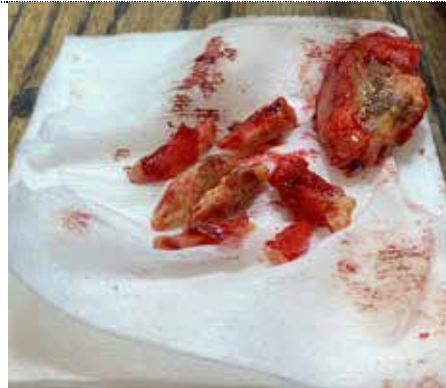104 mid-extraction



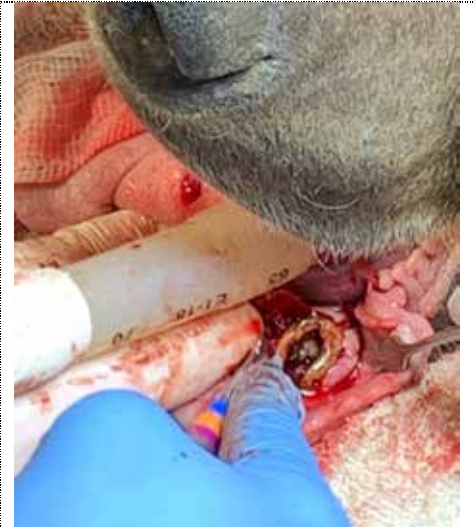104 extraction



104 after extraction



104 and 303-403 extracted teeth



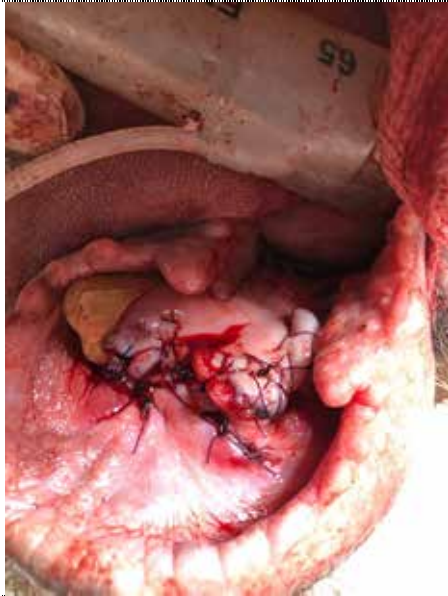304 mid-extraction



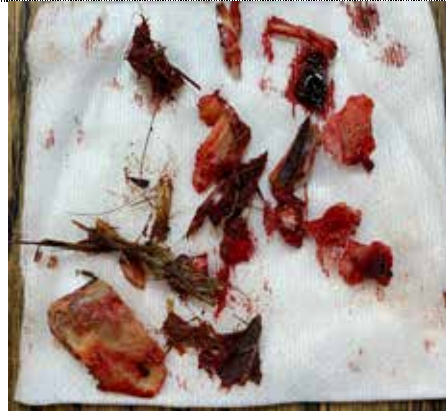VETERINARY DENTISTS without BORDERS
Veterinary Dental Report

MISSION LOCATION
 MISSION CODE
 MISSION DATES

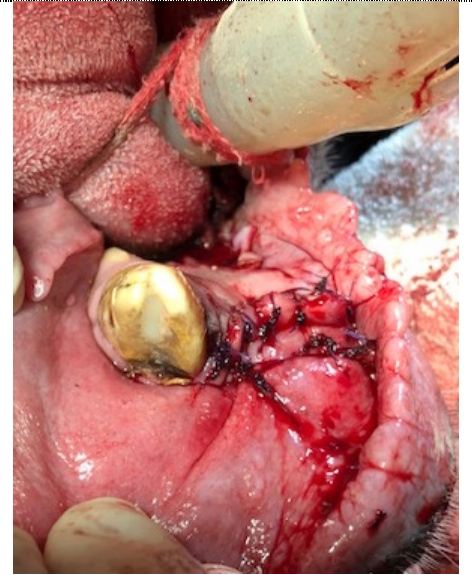Wild Animal Sanctuary
 WAS08FEB20
 February 8, 2020



303 to 304 after extractions

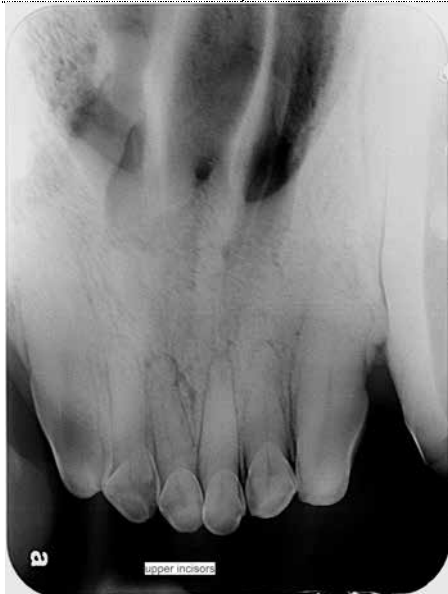

304 extracted tooth fragments and debris removed from the canal therapy

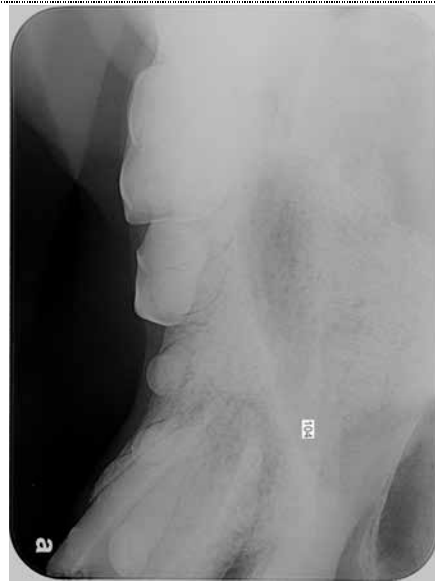

404 after root canal therapy and 303-403 post-extraction

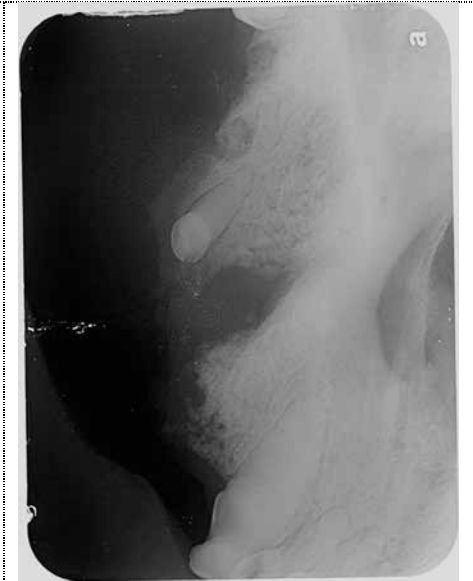
RADIOGRAPHS:



103-203 upper incisors – no treatment



104 B4 SXX surgical extraction



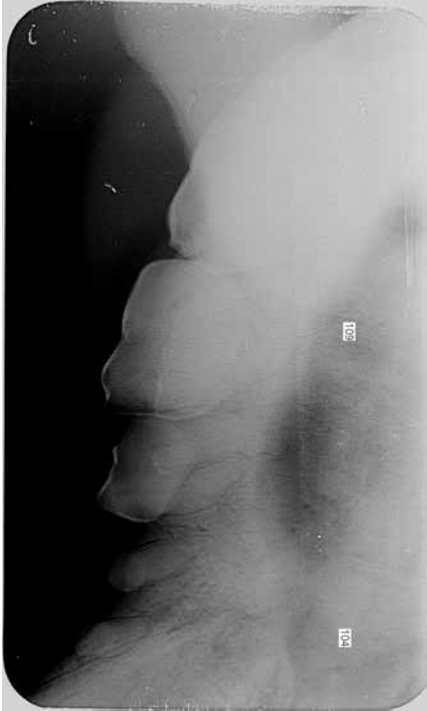104 after SXX



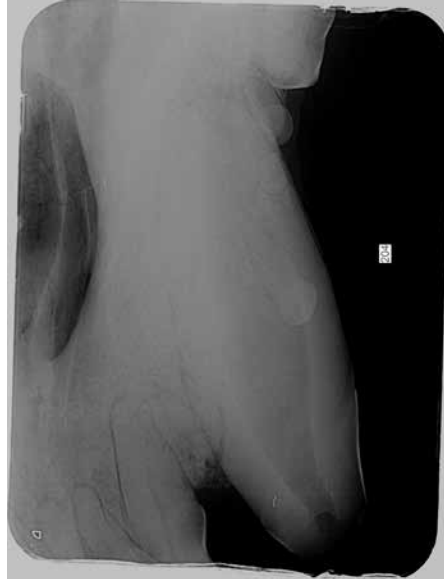VETERINARY DENTISTS without BORDERS
Veterinary Dental Report

MISSION LOCATION
 MISSION CODE
 MISSION DATES

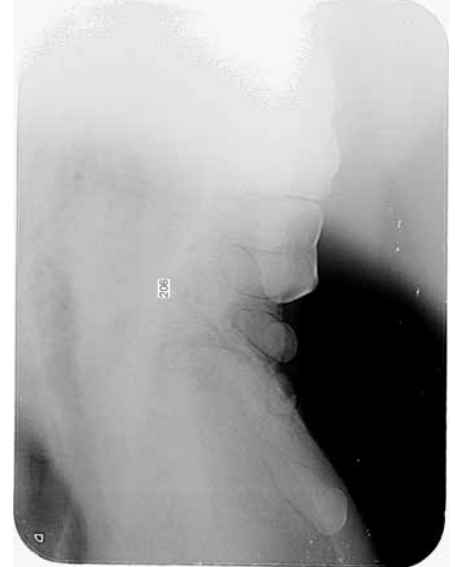Wild Animal Sanctuary
 WAS08FEB20
 February 8, 2020



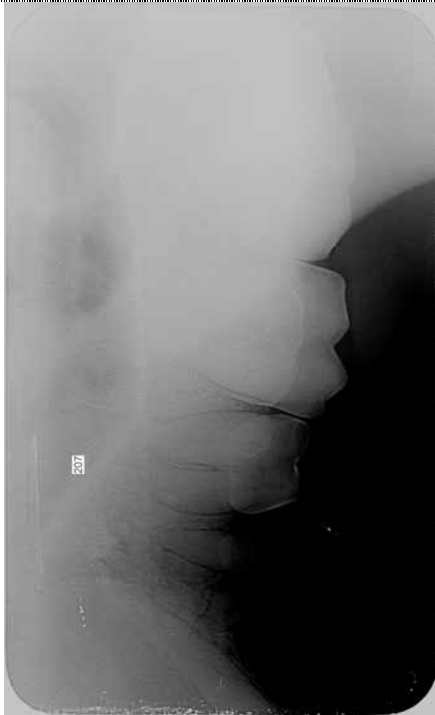109 no treatment required



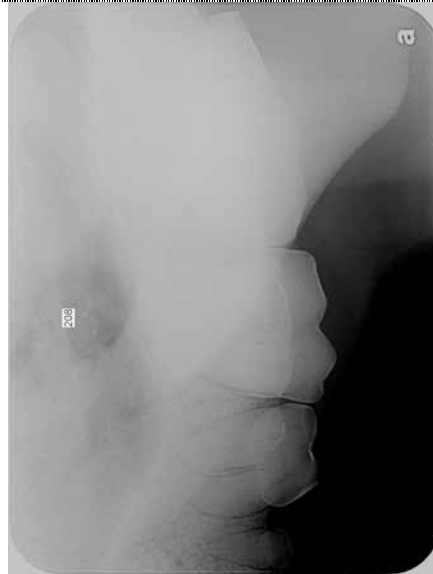204 treatment postponed due to time



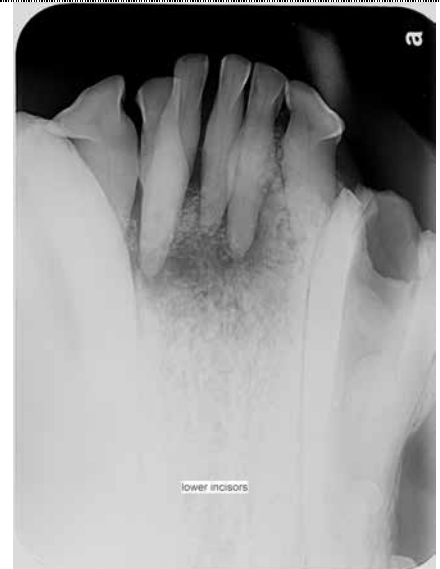206



207



208



303-403 B4 extractions



VETERINARY DENTISTS without BORDERS
Veterinary Dental Report

MISSION LOCATION
 MISSION CODE
 MISSION DATES

Wild Animal Sanctuary
 WAS08FEB20
 February 8, 2020

<p>303 – 403 after extractions. 304 mid-extraction</p>	<p>306 no treatment required</p>	<p>308 no treatment required</p>
<p>304 and 404 before treatment</p>	<p>304 after extraction</p>	<p>404 after RCT root canal therapy</p>






VETERINARY DENTISTS without BORDERS

Veterinary Dental Report

MISSION LOCATION
MISSION CODE
MISSION DATES

Wild Animal Sanctuary
WAS08FEB20
February 8, 2020

		
404 crown after RCT	406 no treatment	408 no treatment

PROGNOSIS:

Good. Patient should be significantly more comfortable after removal and treatment of diseased teeth.

ADDITIONAL COMMENTS:

204 treatment postponed due to time. CCF, closed apex, no sign of periapical abscess.

RECHECK RECOMMENDATIONS:

Check 204 for status. RCT (root canal therapy) if indicated. Check 304 extractions. Retrograde extraction if indicated.